

2012년 2월

석사학위논문

Apical foramen morphology according to the length of merged canal at the apex 김희호

2012년 2월  
석사학위논문

# Apical foramen morphology according to the length of merged canal at the apex

조선대학교 대학원

치 의 학 과

김 희 호



Apical foramen morphology  
according to the length of  
merged canal at the apex

치근단부에서 하나의 근관으로 합병된 길이에 따른  
치근단공의 형태

2012년 2월 24일

조선대학교 대학원

치 의 학 과

김 희 호

Apical foramen morphology  
according to the length of  
merged canal at the apex

지도교수 황 호 길

이 논문을 치의학 석사학위신청 논문으로 제출함.

2011년 10월

조선대학교 대학원

치 의 학 과

김 희 호

김희호의 석사학위논문을 인준함.

위원장   조선대학교   교수   이 상 호   인

위   원   조선대학교   교수   민 정 범   인

위   원   조선대학교   교수   황 호 길   인

2011년 11월

조선대학교 대학원

# CONTENTS

Abstract .....	iv
I. Introduction .....	1
II. Materials and methods .....	3
III. Results .....	6
IV. Discussion .....	9
V. Conclusion .....	11
References .....	12

# TABLE LEGENDS

Table 1. Lj, Dl, Ds, D, and AFS of the specimens ( $n = 20$ ) .....	6
Table 2. Statistical analysis .....	7
Table 3. Statistical analysis of correlatiion between the D and Lj .....	8

## FIGURE LEGENDS

Fig. 1. Lj on radiograph. .... 4

Fig. 2. A criteria of the apical foramen shape ( $\times 50$ ). .... 5



# 국문초록

## 치근단부에서 하나의 근관으로 합병된 길이에 따른 치근단공의 형태

김 희 호

지도교수 황호길

조선대학교 대학원

치의학과

이 연구의 목적은 제 II형 근관의 치근단부에서 하나의 근관으로 진행되는 거리에 따른 치근단공의 형태를 조사하는 것이다.

외흡수 소견이 관찰되지 않은 성숙한 치근을 가진 인간의 상,하악 소구치 20개를 준비하였다. 회전 다이아몬드 디스크를 이용하여 백악-법랑경계 1mm 하방부위에서 치관을 제거하여 치근단부를 획득하였다. 파일 첨부에서 두 근관이 만나는 부위까지의 거리를 측정하였다(Lj). 치근단공의 형태와 크기를 조사하기 위해서 치근단부는 해부학적 근침의 1 mm 상방을 diamond saw (Isomet, Buehler Ltd, Lake Bluff, IL, USA)로 절단하였다. 절단면은 현미경(BX60MF, OLYMPUS OPTICAL Co., LTD, Japan)을 이용하여 50배의 배율에서 관찰되고 치근단공의 모양을 측정하기 위하여 촬영되었다. 치근단공의 최장길이를 최단길이는 ImageJ (1.44p, National Institutes of Health, USA)라는 프로그램을 이용하여 산출되었다. Lj와 치근단공의 모양사이의 상관관계를 Pearson's correlation을 이용하여 분석하였다.

Lj는 평균 3.74 mm (최장: 9.30 mm, 최단: 0.00 mm)이었다. 치근단공 직경의 차(D)

의 평균은  $484.85 \mu\text{m}$  (최고:  $1787.00 \mu\text{m}$ , 최저:  $56.00 \mu\text{m}$ )이었다. 이번 연구에서 Lj와 D사이의 상관관계가 있음이 밝혀졌으며 두 값 사이에는 통계학적으로 유의한 음의 상관관계가 존재하였다 ( $p < 0.05$ ).

결론적으로, Lj가 길면 길수록 치근단공은 타원형이었다. 반대로, Lj가 짧으면 짧을수록 치근단공은 편평한 모양이었다. 그러므로 임상가는 제 II형 근관계의 근관치료시 치근단부에서 하나의 근관으로 합병된 길이에 따른 치근단공의 형태를 고려하여야 한다.

# I . INTRODUCTION

A thorough knowledge of the anatomy of root canal system is required to improve the success rate of endodontic treatment.<sup>1-4</sup> Because the root canal system is complex, and canals may branch, divide, and rejoin taking various pathways to the apex. In clinical situation, clinicians usually depend on two-dimensional radiograph for understanding the anatomy of root canal system. The early recognition of these configurations facilitates cleaning, shaping, and obturation of the root canal system. Unfortunately, two-dimensional radiographic images do not reveal all anatomic characteristics.<sup>5,6</sup>

Furthermore, the apical foramen often does not represent a round shape.<sup>7</sup> Many root canals represent oval or flat apical foramen<sup>8-10</sup> that make measuring the diameter of root canals difficult. With regard to obturation, some studies verified that many of the canal surfaces (especially in the apical region) are not touched during canal preparation because of the oval or irregular configuration.<sup>11-13</sup> These untouched canal surfaces may account for the failure of endodontic treatment.

Weine<sup>14</sup> categorized the root canal systems in single root into four basic types: Type I -single canal from the pulp chamber to the apex; Type II -two separate canals leaving the chamber but merging short of the apex to form only one canal; Type III-two separate canals leaving the chamber and exiting the root in separate apical foramina; Type IV-one canal leaving the pulp chamber but dividing short of the apex into two separate and distinct canal with separate apical foramina. Vertucci FJ et al.<sup>15</sup> had reported the anatomy of Type II root canal systems. The complexity of Type II root canal systems prevents these canals from being cleaned, shaped, and obturated effectively during root canal therapy. Once recognized, the type II root canal systems provide challenges with respect

to debridement and obturation. In point of debridement, Jeong et al. compared the sizes of master apical file by instrumentation in type II root canal systems.<sup>16</sup>

The aim of this study is to investigate the relationship between the apical foramen shape and size according to the length of merged canal at the apex in type II root canal system.

## II. MATERIALS AND METHODS

### A. Selection and preparation of teeth

The teeth were collected from a general dental practice and had been extracted for pulpal, periodontal, and orthodontic reasons. This study included intact extracted maxillary and mandibular human premolars ( $n = 20$ ) with fully formed roots without any visible signs of external resorption. None of these teeth had prior root canal treatment.

The teeth were manually cleaned from the calculus and periodontal tissues. The teeth were stored in a 0.1% chlorhexidine solution. Preoperative radiographs were taken to estimate the root canal type. And the teeth with Type II root canal systems were classified.

The root segments were obtained by removing the crown 1.0 mm beneath the cementum-enamel junction (CEJ) using rotary diamond disk. The root canals were negotiated with a size 10 K hand file to avoid modifying the canal's apical anatomy and irrigated with 5.25% sodium hypochlorite.

### B. Measurement

The reference length of the root canal was measured as follows. Firstly, a size 10 K hand file inserted into the root canal until the file tip was visible at the apical foramen. Another 10 K hand file inserted into the root canal until the file tip was joined with existing file. The two 10 K hand files joined at the point. The distance between the file tip and merged point of joining two canals was defined as Lj. And Lj was measured using ImageJ program (1.44p, National Institutes of Health, USA). Postoperative radiographs were taken to estimate Lj (Figure 1).

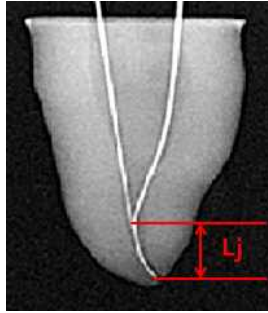


Figure 1. Lj on radiograph.


### C. Evaluation

The specimens were embedded in epoxy resin. After the epoxy resin had set, the roots were carefully sectioned at 1mm from the apex by slow-speed water-cooled diamond saw (Isomet, Buehler Ltd, Lake Bluff, IL, USA) positioned perpendicularly to the root canal and prepared for microscopic analysis.

Each cross section was prepared with EDTA irrigant (PREP EDTA Gel, Vision, Seoul, Korea) for 5 minutes, then rinsed with saline and dried. Then each cross section was stained with methylene blue to highlight the contours of the root canal, then rinsed with saline and dried.

All cross sections were examined under the microscope (BX60MF, OLYMPUS OPTICAL Co., LTD., Japan) at  $\times 50$  magnification and photographed to estimate the shape of the apical foramen. The longest and the shortest diameter of apical foramen was measured using ImageJ program (1.44p, National Institutes of Health, USA).

Criteria of the apical foramen shapes were as follows. Oval shape was the larger diameter than the smaller exceeded by more than the radius. And flat shape was long-to-short canal diameter ratio greater than 2 (Figure 2).



(a) Oval

(b) Flat

**Figure 2.** A criteria of the apical foramen shapes ( $\times 50$ ). Oval shape is that the larger diameter than the smaller exceeded by more than the radius (a). And flat shape is that long-to-short canal diameter ratio greater than 2 (b).

#### D. Statistical analysis

For each cross section, the difference (D) between the longest (Dl) and the shortest diameter (Ds) was related to Lj. Correlation coefficient was calculated to identify the link between Lj and the apical foramen shape by Pearson' s correlation. The apical foramen shape was indentified an oval or flat.

All datum were summarized with means, maximum, minimum, standard deviation (SD) and analysed correlation between Lj and the apical foramen shape using the software SPSS version 17.0 (SPSS Inc, Chicago, IL, USA).

### III. RESULTS

The distance between the file tip and merged point of joining two canals (Lj), the longest diameter (Dl), the shortest diameter (Ds), difference (D) between Dl and Ds and the apical foramen shape (AFS) was shown in the Table 1. The apical foramen shapes from this study were classified as oval and flat.

**Table 1.** Lj, Dl, Ds, D, and AFS of the specimens ( $n = 20$ )

	Lj (mm)	Dl ( $\mu\text{m}$ )	Ds ( $\mu\text{m}$ )	D ( $\mu\text{m}$ )	AFS
1	9.30	507	393	114	Oval
2	5.44	393	329	64	Oval
3	2.86	513	301	212	Oval
4	2.94	451	317	134	Oval
5	3.56	849	336	513	Flat
6	3.64	864	493	371	Oval
7	1.94	699	256	443	Flat
8	2.88	404	348	56	Oval
9	6.16	399	337	62	Oval
10	0.00	1861	75	1786	Flat
11	1.32	780	132	648	Flat
12	4.14	1279	345	934	Flat
13	1.82	1028	500	528	Flat
14	3.38	1480	221	1259	Flat
15	5.26	451	284	167	Oval
16	2.80	908	349	559	Flat
17	4.20	607	521	86	Oval
18	0.28	525	152	373	Flat
19	8.70	391	227	164	Oval
20	4.24	1623	395	1228	Flat



Lj, the distance between the file tip and merged point of joining two canals; Dl, the longest diameter; Ds, the shortest diameter; D, difference between Dl and Ds; AFS, the apical foramen shape.

The average of Lj was 3.74 mm (Max: 9.30 mm, Min: 0.00 mm). The average of D, estimated by taking the shortest diameter from longest diameter of the apical foremen, was 484.85  $\mu\text{m}$  (Max: 1787.00  $\mu\text{m}$ , Min: 56.00  $\mu\text{m}$ ) (Table 2).

**Table 2.** Statistical analysis

	No.	Minimum	Maximum	Mean	SD
Lj (mm)	20	0.00	9.30	3.74	2.39
D ( $\mu\text{m}$ )	20	56.00	1787.00	484.85	478.54

Lj, the distance between the file tip and merged point of joining two canals; D, difference between Dl and Ds; Dl, the longest diameter; Ds, the shortest diameter.

The shape of the apical foramen was recognized depending on the D. When the D was close to zero, the apical foramen shape was close to oval. When the D was far from zero, the apical foramen shape was close to flat. We hypothesized that if Lj is longer, D is close to zero. To prove this hypothesis, we calculated a correlation coefficient (Pearson correlation). Table 3 showed the correlation coefficient of two variables. Since it was minus figure (- 0.452) and statistically significant ( $p < 0.05$ ), there was inverse correlation between Lj and D. Therefore, the hypothesis was reasonable.

**Table 3.** Statistical analysis of correlation between D and Lj

		Lj	D
Lj	Pearson correlation	1	- 0.452 †
	Sig. (2-tailed)		0.045
	No.	20	20
D	Pearson correlation	- 0.452 †	1
	Sig. (2-tailed)	0.045	
	No.	20	20

† Correlation is significant at the 0.05 level (2-tailed).

Lj, the distance between the file tip and merged point of joining two canals; D, difference between Dl and Ds; Dl, the longest diameter; Ds, the shortest diameter.

Therefore, in condition of the type II root canal system, the longer Lj was, the more D became short, and the shorter Lj was, the more D became long. Namely, the longer Lj was, the more contour of apical foramen became oval. On the contrary, the shorter Lj was, the more contour of apical foramen became flat.

## IV. DISCUSSION

Successful endodontic treatments require the knowledge of the apical foramen shape and size. It is essential to determine the size of apical preparation. The observations of the apical foramen shape in the present study are in disagreement with previous findings. Martos et al. found that the most frequent root apex morphology and apical foramen in the maxillary and mandibular teeth was the round shape followed by the oval shape.<sup>10</sup> But, major findings from these samples included demonstration of oval and flat shape of the apical foramen as same proportion (each 50%). In this study, only Type II root canal systems were examined. So, we observed oval and flat apical foramen shape.

In this point of view, the mechanical canal enlargement might be insufficient for cleaning the type II root canal systems. Therefore, irrigations with chemical solution such as NaOCl, CHX, and EDTA were also very important for disinfection of the root canal.<sup>17,18</sup>

There is little controversy about the size of the apical preparation and its importance is significant when considering the best possible debridement of infected root canals.<sup>19,20</sup> To determine the size of apical preparation in clinical situation, clinicians might use the two-dimensional radiographic image. This procedure reflect the clinical situation. Clinician might measure the distance between file tip and the merged point of joining two canals. Jou YT et al.<sup>21</sup> suggested constant criteria to estimate the apical foramen shape. As it become shorter, the apical foramen become more flat shape. So, the size of the apical preparation should be considered for mechanical debridement of infected root canals.

Although the present study clearly showed the negative correlation between Lj and D, it had several limitations, which need to be mentioned. The methodology used to calculate the morphology, the different ages of

specimens and the small number of groups investigated could cause slight variation.<sup>22</sup> Some specimens had curved root canals. So, it was difficult to measure the length of specimens. And we had used the two-dimensional radiographic image to measure the file length. Unfortunately, the two-dimensional radiographic image was not revealed all anatomic characteristic. The different ages of specimens probably could interfere and modify the results of the anatomic evaluation. The reason is that the constant remodeling of the root apex was occurred through cementum apposition and resorption.<sup>23</sup>

There are few articles about the length of merged canal in type II root canal system. In this study, the average of Lj was 3.74 mm (Max: 9.30 mm, Min: 0.00 mm). Park JW et al.<sup>24</sup> mentioned about the length of merged canal in maxillary first molar mesiobuccal root. But the data is a little different to the findings of this study. This difference may be caused by the type of teeth.

In this study, oval and flat apical foramen shapes were observed. These types of apical foramen were difficult to measure the diameter of apical foramen. And it was impossible to remove the debris with only mechanical instrumentation. So, it needs to be considered using endodontic instrument, which do not touch the certain surface of the root canal system. Also, a better method of cleansing and disinfecting the root canal should be researched.

The observations made here will provide a more precise understanding of the type II root canal system. In the next study, we need to classify the teeth according to a type. Correlation between the file length (Lj) and the difference of diameter in each type of the teeth will be understood in the future.

## V. CONCLUSION

There was inverse correlation between Lj and D. As the distance between the file tip and merged point of joining two canals gets longer, the apical foramen becomes more oval shape. On the contrary, as it gets shorter, the apical foramen becomes more flat shape. Therefore, clinician should consider the apical foramen shape and size according to the length of merged canal during root canal instrumentation in type II root canal system.

## REFERENCES

1. Baratto Filho F, Zaitter S, Haragushiku GA, et al. Analysis of the internal anatomy of maxillary first molars by using different methods. *J Endod* 2009;35:337-42.
2. Olson DG, Roberts S, Joyce AP, Collins DE, McPherson JC, 3rd. Unevenness of the apical constriction in human maxillary central incisors. *J Endod* 2008;34:157-9.
3. Hassanien EE, Hashem A, Chalfin H. Histomorphometric study of the root apex of mandibular premolar teeth: an attempt to correlate working length measured with electronic and radiograph methods to various anatomic positions in the apical portion of the canal. *J Endod* 2008;34:408-12.
4. Vertucci FJ. Root canal anatomy of the human permanent teeth. *Oral Surg Oral Med Oral Pathol* 1984;58:589-99.
5. Olson AK, Goerig AC, Cavataio RE, Luciano J. The ability of the radiograph to determine the location of the apical foramen. *Int Endod J* 1991;24:28-35.
6. Jafarzadeh H, Wu YN. The C-shaped root canal configuration: a review. *J Endod* 2007;33:517-23.
7. Grande NM, Plotino G, Pecci R, Bedini R, Pameijer CH, Somma F. Micro-computerized tomographic analysis of radicular and canal morphology of premolars with long oval canals. *Oral Surg Oral Med Oral Pathol Oral Radiol Endod* 2008;106:e70-6.
8. Wu MK, Barkis D, Roris A, Wesselink PR. Does the first file to bind correspond to the diameter of the canal in the apical region? *Int Endod J* 2002;35:264-7.
9. Wu MK, R'Oris A, Barkis D, Wesselink PR. Prevalence and extent of long oval canals in the apical third. *Oral Surg Oral Med Oral Pathol*

- Oral Radiol Endod* 2000;89:739-43.
10. Martos J, Lubian C, Silveira LF, Suita de Castro LA, Ferrer Luque CM. Morphologic analysis of the root apex in human teeth. *J Endod* 2010;36:664-7.
  11. Wu MK, Wesselink PR. A primary observation on the preparation and obturation of oval canals. *Int Endod J* 2001;34:137-41.
  12. Weiger R, Bartha T, Kalwitzki M, Lost C. A clinical method to determine the optimal apical preparation size. Part I. *Oral Surg Oral Med Oral Pathol Oral Radiol Endod* 2006;102:686-91.
  13. Jung IY, Seo MA, Fouad AF, et al. Apical anatomy in mesial and mesiobuccal roots of permanent first molars. *J Endod* 2005;31:364-8.
  14. Weine FS, editor. *Endodontic Therapy*. 5th ed. St Louis: Mosby; 1996. p243.
  15. Vertucci F, Seelig A, Gillis R. Root canal morphology of the human maxillary second premolar. *Oral Surg Oral Med Oral Pathol* 1974;38:456-64.
  16. Jeong EJ, Lee DK, Baek SY, Hwang HK. A comparison of master apical file size according to instrumentation in type II root canal. *J Kor Acad Cons Dent* 2008;33:435-442.
  17. Shin JS, Cho YB. Removal patterns of smear layer according to application temperature and time of EDTA. *J Kor Acad Cons Dent* 2002;27:535-542.
  18. Lee JK, Park SH, Choi GW. Time-dependent effects of EDTA application on removal of smear layer in the root canal system. *J Kor Acad Cons Dent* 2006;31:169-178.
  19. Senia ES. Canal diameter: the forgotten dimension. *Dent Today* 2001;20:58-62.
  20. Peters OA. Current challenges and concepts in the preparation of root canal systems: a review. *J Endod* 2004;30:559-67.

21. Jou YT, Karabucak B, Levin J, Liu D. Endodontic working width: current concepts and techniques. *Dent Clin North Am* 2004;48:323-35.
22. Blaskovic-Subat V, Maricic B, Sutalo J. Asymmetry of the root canal foramen. *Int Endod J* 1992;25:158-64.
23. Oyama K, Motoyoshi M, Hirabayashi M, Hosoi K, Shimizu N. Effects of root morphology on stress distribution at the root apex. *Eur J Orthod* 2007;29:113-7.
24. Park JW, Lee JK, Ha BH, Choi JH, Perinpanayagam H. Three-dimensional analysis of maxillary first molar mesiobuccal root canal configuration and curvature using micro-computed tomography. *Oral Surg Oral Med Oral Pathol Oral Radiol Endod* 2009;108:437-42.