[UCI]I804:24011-200000256756

2012년 2월
석사학위논문

Socket preservation with biphasic calcium phosphate in humans

조선대학교 대학원

치 의 학 과

방 경 일

Socket preservation with biphasic calcium phosphate in humans

사람에서 이상 인산칼슘을 이용한 발치와 보존술

2012년 2월 24일

조 선 대 학 교 대 학 원

치 의 학 과

방 경 일

Socket preservation with biphasic calcium phosphate in humans

지도교수 김 병 옥

이 논문을 치의학 석사학위신청 논문으로 제출함

2011년 10월

조 선 대 학 교 대 학 원

치 의 학 과

방 경 일

방경일의 석사학위논문을 인준함

위원장 조선대학교 부 교 수 김 학 균 (인)

위 원 조선대학교 전임강사 유 상 준 (인)

위 원 조선대학교 교 수 김 병 옥 (인)

2011 년 11 월

조 선 대 학 교 대 학 원

Contents

List of Figures

List of Table

국문초록

사람에서 이상 인산칼슘을 이용한 발치와 보존술

방 경 일
지도교수 : 김병옥
치의학과
조선대학교 대학원

치아 상실 후 종래의 보철물 및 골내 임플란트의 적절한 기능 및 향상된 심미를 위해서는 적당한 치조제 폭경이 요구되고 있으나 안타깝게도 치아의 상실이 일어나면 생리적인 치유의 결과로 치조골의 흡수가 발생된다. 이는 경조직 뿐 아니라 연조직의 위축을 일으켜 추후의 치료에 있어 불리하게 작용할 수 있다. 이를 극복하기 위한 다양한 방법들이 있으며 그 중 발치와 보존술은 비교적 술식이 간단하며 골의 위축을 방지하여 성공적인 임플란트 및 보철 치료를 위한 적절한 골 폭 및 높이를 유지시킬 수 있는 장점을 지닌다. 술자에 따라 차단막과 함께 혹은 차단막 없이 다양한 종류의 골 이식재를 이용한 발치와 보존술이 시행될 수 있으며 그 중 자가골은 골형성 세포를 제공할 수 있는 장점이 있어 가장 선호되는 골 이식재였으나 공여부 형성 및 환자의 불편감으로 점점 사용이 줄어드는 추세에 있다.

이 연구는 인체의 뼈를 구성하는 Calcium과 Phosphate를 주성분으로 하여 새로이 만들어진 이상 인산칼슘 이식재 (BCP)를 사용하여 발치와 보존술을 시행하고 3개월 후 임상적 및 조직학적으로 그 효과를 평가하고자 시행되었다.

이 연구를 위하여 보존 불가능한 치아나 동요도가 있는 임플란트를 가진, 전신적으로 건강하며 비흡연자인 성인 5명을 대상으로 이상 인산칼슘 이식재와 흡수성 콜라겐 차단막을 이용하여 발치와 보존술을 시행하였다. 대상 치아 또는 임플란트 발거 직후 해당 부위 치조제의 중간부의 협설 폭, 인접치의 Cementoenamel junction을 기준으로 협측 중간부의 치은연까지의 거리, 설측 중간부의 치은연까지의

거리를 평가하였다. 3개월의 치유기간 후 해당 부위의 임상적인 검사를 시행하고 임플란트 식립시 2mm 트레핀 버로 조직 생검을 위한 조직을 채취하였다. 생검된 골조직을 표본으로 제작한 뒤 신생 골, 연조직, 골수 등을 백분율로 평가하였다.

연구결과 임상적인 지표에서의 변화가 관찰되었지만 협측 골 높이를 제외하고는 통계적으로 유의하지 않을 만큼의 변화를 보였다. 조직학적 분석에서는 신생골의 형성을 확인할 수 있었다.

본 연구에서 사용된 합성골 이식재는 발치 후 발생하는 치조제의 부피 감소를 줄일 수 있었다. 뿐만 아니라 이식재의 부분적인 흡수를 통한 새로운 골의 형성이 관찰되었고 이로써 골 전도성이 있음을 확인할 수 있었다.

I. Introduction

Adequate alveolar ridge dimension is required for conventional prosthesis and dental implant to accomplish their proper function and improved esthetic. But, unfortunately, after the loss of teeth, healing of extraction socket leads to the loss of alveolar ridge width and height.[1] The estimated structural loss is about 40% and 60% of preextraction alveolar ridge height and width, respectively.[2] And the healing process after tooth extraction apparently results in a more pronounced resorption on buccal aspect than the lingual/palatal aspects of the ridge.[3] This loss makes it hard for dentists to have optimal esthetic and functional result because this can lead to the lack of available bone and soft tissue for implant placement, an unfavorable crown-implant ratio, and esthetic problems in the anterior area.

To cope with this kind of complication, various techniques have been used. Augmentation of the extraction socket has been used to maintain or enhance the dimensions of the alveolar bone and soft tissue based on the principles of guided bone regeneration (GBR).[4-7] Among them, socket preservation is a technique that the graft material is placed in the socket at the time of extraction to preserve the alveolar ridge. Various types of graft materials can be utilized for this technique, such as autograft, allograft, xenograft, and alloplast materials in combination with or without a barrier membrane. Autogenous bone has been recognized as the "gold standard" of bone grafting material because of the viability of transferable osteogenic cells within the graft but the disadvantage of second donor site morbidity and patient discomfort have led to a decline in the popularity of this material.[8]

Allografts have demonstrated their osteoconductive potential but there is much controversy about its clinical significance of this potential.[9-13] And uncertain immune response and risk of disease transmission can not be

excluded. Currently, xenografts are usually used because of the benefits of its unlimited availability and reduced flaws associated with the autografts. Some investigators indicated that bovine bone-grafted sites demonstrated good results for implant placement and this material could be a good bone substitutes for bone augmentation before implant placement.[14,15] But this material also has drawbacks which includes its slow resorbability, healing with the form of fibrous encapsulation and the potential risk of bovine spongiform encephalopathy.[16-18] Alloplast material, though with the disadvantage of slow resorbability, has many advantages over other types of material. It can be supplied easily, manufactured with various types and free of inflammation.[19]

Among many types of synthetic bone substitutes, biphasic calcium phosphate (BCP) which is composed of hydroxyapatite and beta-tricalcium phosphate has been used for surgical procedures such as sinus lifting, bone augmentation, periodontal surgery, and ridge preservation.[4,20,21] This material can facilitate bone regeneration by osteoconduction. Beta-tricalcium phosphate can be completely resorbed and replaced by regenerative bone, which provides for faster bone remodeling. In the mean time, hydroxyapatite is slowly resorbed and serves as a scaffold for new bone formation. In this study, a newly invented synthetic bone substitute composed of 60% hydroxyapatite and 40% beta-tricalcium phosphate (Genesis-BCP; DIO, Busan, Korea) was used for socket preservation technique. The purpose of this study was to evaluate cliniclal and histologic effectiveness of this material as graft material in socket preservation technique and further, to determine if this material might be a suitable substitute for existing bone graft material.

Ⅱ. Materials and methods

A. Patient selection

This study was for a prospective study with clinical trial. The study protocol was approved by The Institutional Review Board of Chosun University Dental Hospital(CDMD111255). Written informed consent was signed by all participants. Total 5 patients enrolled in this study who had teeth that can not be conserved or mobile implants and subsequently restored with implant treatment. The reasons for extraction were tooth fracture, endodontic failure, or failed osseointegration of implant. Exclusion criteria included patients with systemic diseases that may affect normal healing, current pregnancy or breast-feeding, and being a heavy smoker (≥10 cigarettes/day)

B. Surgical procedures

After taking periapical radiograph, local anesthesia and extraction followed. For atraumatic extraction, flapless technique was performed. After careful extraction, Clinical parameters including buccolingual width, buccal crest height and lingual crest height were evaluated. Buccolingual width measurement was performed at 3mm apical to the cemento-enamel junction of the adjacent tooth. Buccal and lingual crest height measurements evaluated the distance from the gingival margin in the middle area of the extraction socket to the reference point. And the reference point was the cemento-enamel junction of the adjacent tooth (Fig.1). Thorough debridement and saline irrigation in the socket were done for the removal of granulation tissues. Following the socket repair technique proposed by Elian et al.,[27] a resorbable collagen barrier membrane (Bio-Gide, Geistlich Pharma AG, Wolhusen, Switzeland) was inserted into the inner side of the bone wall which had severe bone loss. Then the socket was

grafted with BCP and the other end of the membrane covered the socket to maintain the graft material. The surgical site was sutured with by horizontal figure-of-eight suture or several interrupted sutures (Fig.2).

Postoperatively, systemic antibiotics were prescribed for 5 days and the patient was advised to rinse with 0.1% chlorhexidine gluconate mouthwash, 1 minute, twice daily for 2 weeks. Patients were evaluated for whether they have any unexpected response at 1 month, 2 month, and 3 month.

After healing period of 3 months, clinical evaluation was performed by the parameters which were used before socket preservation procedure. Then the flaps were reflected for implant placement. The specimens were harvested with a 2.0mm trephine bur at the core of the socket in the process of surgery (Fig.3).

C. Histologic analysis

Specimens were immediately fixed in 10% buffered formalin solution for 24 hours and decalcified in 10% EDTA acid for 10 days. After dehydration in ascending alcohol series, the specimens were embedded in paraffin and then 5 ㎛ thick sections parallel to the longitudinal axis of the biopsy specimen were prepared using a microtome. Sections were stained with Mayer's hematoxyline & eosin for light microscopy.

Histomorphometry was performed by a computerized technique; Photomicrographs were taken by an Olympus BH2 microscope equipped with an Olympus DP50 digital camera (Olympus Optical Company Ltd, Japan). Measurement fields were selected by visual monitoring of the microscopic image on screen. After digitization of the picture, Image processing was performed with image analysis system (*i*MTimageanalysissoftware, *i*MTechnology, Daejeon, Korea).

D. Statiscal analysis

Clinical parameters of ridge width, buccal crest height, and lingual crest height were used for statistical analysis. Comparisons between baseline and 3 months later were performed with the Wilcoxon Signed-Rank test. The data were presented as mean±standard deviation with a significance level of $P<0.05$. A statistical software program was used for data analysis(SPSS, SPSS Ver. 17.0 Inc., Chicago, IL, USA).

Ⅲ. Results

The five patients who had undergone socket preservation using synthetic BCP bone-grafting material were analyzed. No patient dropped out. All patients subsequently received a dental implant treatment. At the time of extraction, none of the sites had acute or active inflammation. In one case, there was mild inflammation on the gingival tissue but no severe reactions like infection and suppuration were detected.

After a 3-month healing period, there was little change in clinical parameters and all sites maintained satisfactory bone and soft tissue contours. At the time of re-entry, newly formed hard tissues and BCP granules were well consolidated but the regenerated bone was distinguishable from the surrounding natural bone. Collagen membranes were not found at the surgical site.

A. Clinical evaluation

The result comparing clinical parameters of postextraction and 3 months later showed that there were no statistically significant changes in buccolingual width and lingual crest height. But, in buccal crest height, there was statistically significant change. (Table 1, 2)

B. Histologic and histomorphometric evaluation

The specimens taken at the time of implant placement showed that the newly formed bone tissue is fused directly to the graft material without fibrous tissue insertion. And the graft material was partially resorbed as the new bone tissue grows into the material. At some graft particles, the resorption by polymorphonuclear leucocytes showed but there was no specific infiltration of inflammatory cells (Fig.4). The mean percentage of soft tissue, residual graft particles, and newly formed bone were 61.42%, 15.50%, and 28.84%.(Table 3, 4)

Ⅳ. Discussion

Previous studies had shown that significant alveolar bone volume reduction as a result of bone resorption after tooth loss. Approximately one third of this loss occurred in the first 3 months with a loss of up to 50% of alveolar ridge volume over a 12-month period.[1,4] This loss has a detrimental effect on potential treatment with a dental implant or conventional prosthesis, especially in the maxillary anterior area.

Various procedures have been proposed to prevent this alveolar ridge resorption. Procedures like immediate implant placement,[22,23] and bone grafting[24] are attempted to prevent ridge remodeling. But any method cannot completely eliminate this change.

The need and efficacy of socket preservation has been debated. Some researchers believe that socket preservation cannot prevent the resorption of extracted socket walls and the quality of new bone cannot be guaranteed. But still, many other researchers agree with the necessity of socket preservation because this procedure can maintain the shape of soft tissue and hard tissue. And also, the need for additional augmentation can be reduced.[22]

This clinical study evaluated the efficacy of socket preservation performed with BCP combined with resorbable collagen membrane. The key difference in this study is that, unlike existing BCP synthetic bone, selected bone substitute(Genesis-BCP) has particular surface structure. The surface of each particle is composed of several pieces of HA and beta TCP like a soccer ball.

In comparison of the clinical parameters between baseline and 3 months, ridge width, buccal crest height, and lingual crest height showed some changes. But in statistical analysis, the data of buccolingual width and the lingual crest height change showed no significance. Although the change in ridge dimension after tooth extraction is unevitable, the result of these clinical parameters

indicate that socket preservation with BCP can effectively reduce ridge dimension resorption following tooth extraction. On the buccal side, there was statistically significant change in ridge height. Araújo et al.[3] concluded that there is a more pronounced resorption on buccal aspect than lingual aspects of the ridge.

Since the buccal bone plate was thinner than the lingual plate, this "horizontal resorption" may also cause "vertical reduction" of the buccal wall. The noticeable change of buccal crest height in this study may result from the characteristics of buccal bone.

In histologic analysis, all of the examined biopsies had connective tissue as a predominant component of the specimen and it was in accordance with previous studies. De Coster et al.[25] studied specimens from BCP-augmented sockets and found the tissue was mainly composed of loosely arranged connective tissue and mineralized bone. Although the main component was connective tissue, in this study, newly formed bone was in direct contact with the grafted particles without any insertion of fibrous connective tissue. The mean percentage of new bone formation was 28.84 ± 5.33% and this result is in the range of previous studies of the same graft material used in maxillary sinus grafting,[21,26] or socket preservation procedures.[4] The grafted materials were partially resorbed with new bone formation. When focusing on the amount of residual particles, the mean percentage of residual BCP particles was 15.50 ± 7.68% after 3-month healing period. This was in the same range as other bone substitutes used for preserving alveolar ridge procedures ranging between 13.5% and 42.0%.[4] As previous study proposed, the limit set for acquiring successful implant installation is 40%[26], and socket preservation with BCP may play a positive role in future site development of implant installation.

In this study, the healing time was limited to 3 months because the purpose of this study was to determine the effectiveness of the selected grafting material for socket preservation procedures over this short period of healing

time. In this short period of healing time, not only proper amount of residual graft material for successful implant installation but also new bone formation through graft material resorption were confirmed. Previous study indicated that an increasing vital bone volume had been found in a BCP augmented sinus from 6 to 8 months.[26] And this finding implies that a longer period of healing time is helpful for new bone formation in a BCP augmented site. This is in line with the observation of this study. Although there was some degradation of graft material in a shorter period of time, still there were graft particles left unchanged and the newly formed bone tissue was evidently different from the existing bone tissue. With an increased healing time, we can expect more amount of newly formed bone and increased bony textural maturity.

V. Conclusion

The clinical and histological investigation of socket preservation with bipahsic calcium phosphate showed an positive result in preserving alveolar ridge dimension after tooth loss. Also, moderate vital bone formation could be observed after 3-month healing period and the amount of unresorbed graft particles were acceptable for implant installment. In conclusion, socket preservation with BCP can effectively maintain ridge dimension after tooth extraction, promote new bone formation by means of osteoconductivity and reduce the need for future ridge augmentation before dental implant placement.

Figures

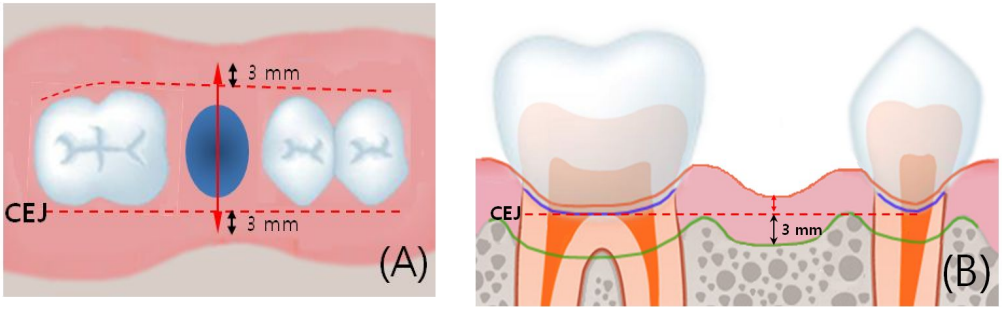

Figure 1. Schematic diagram of clinical parameters. (A) Occlusal view of buccolingual width(red arrow). After marking the point 3mm apically away from CEJ, buccolingual width was measured with periodontal probe. (B) Lateral view of reference point(CEJ) and clinical parameter of buccal/lingual crest height(red arrow).

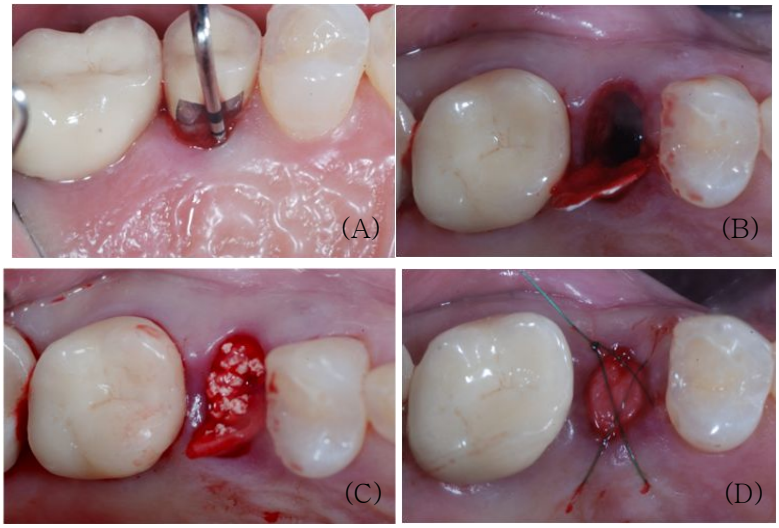

Figure 2. Clinical photograph of the socket preservation procedure. (A) Clinical evaluation of the target tooth. (B) Resorbable collagen membrane was placed into the extraction socket. (C) BCP was grafted inside the extraction socket. (D) Resorbable collagen membrane covered the graft material and was sutured

with horizontal figure-of-eight suture.

Figure 3. Procedure of taking specimen and placing implant. (A) After flap elevation, newly formed bone was incorporated with graft particles. (B) Specimen core was taken with 2mm trephine bur. (C) Implant was placed.

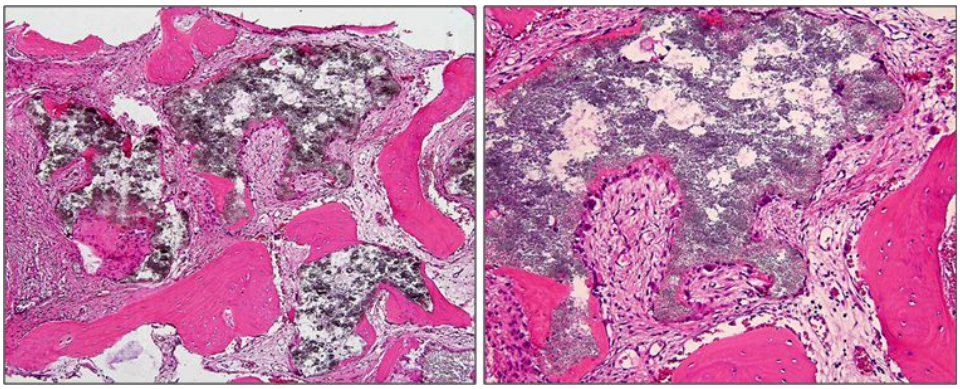

Figure 4. Histology from BCP grafted sites after 3 months. Newly formed bone was in contact with graft particles.

Table

Table 1. Values from clinical evaluation

	Buccolingual width(mm)	Buccal crest height(mm)	Lingual crest height(mm)
Pt. 1			
Baseline	8	3	3
3 month	7.5	5	3
Pt. 2			
Baseline	10	0	0
3 month	9.5	2	0
Pt. 3			
Baseline	9	2	2
3 month	8	3	2
Pt. 4			
Baseline	8	0	0
3 month	8	1	0.5
Pt. 5			
Baseline	8	2	2
3 month	8	4	2

Table 2. Changes in ridge dimensions (mean±SD)

	Baseline(mm)	3 months(mm)	P-value
Buccolingual width	8.60 ± 0.89	8.20 ± 0.76	0.99
Buccal crest height	1.40 ± 1.34	3.00 ± 1.58	0.003
Lingual crest height	1.40 ± 1.34	1.50 ± 1.22	0.374

Table 3. Histomorphometric composition of each specimen(%)

	Residual graft particles	Newly formed bone	Soft tissue
Pt. 1	13.6	30.4	56
Pt. 2	21	21.5	57.5
Pt. 3	18.8	29	81
Pt. 4	21.2	27.1	51.7
Pt. 5	2.9	36.2	60.9

Table 4. Histomorphometric results (mean ± SD)

	Percentage(%)
Residual graft particles	15.50 ± 7.68
Newly formed bone	28.84 ± 5.33
Soft Tissues	61.42 ± 11.43

References

1. Schropp L, Wenzel A, Kostopoulos L, Karring T. Bone healing and soft tissue contour changes following single-tooth extraction: a clinical and radiographic 12-month prospective study. *Int J Periodontics Restorative Dent* 2003;23:313-23.

2. Werbitt MJ, Goldberg PV. The immediate implant: bone preservation and bone regeneration. *Int J Periodontics Restorative Dent* 1992;12:206-17

3. Araújo MG, Lindhe J. Dimensional ridge alterations following tooth extraction. An experimental study in the dog. *J Clin Periodontol* 2005;32:212-8

4. Kesmas S, Swasdison S, Yodsanga S, Sessirisombat S, Jansisyanont P. Esthetic alveolar ridge preservation with calcium phosphate and collagen membrane: preliminary report. *Oral Surg Oral Med Oral Pathol Oral Radiol Endod* 2010;110:e24-36.

5. Fowler EB, Breault LG, Rebitski G. Ridge preservation utilizing an acellular dermal allograft and demineralized freeze-dried bone allograft: Part II. Immediate endosseous implant placement. *J Periodontol* 2000;71:1360-4.

6. Bartee BK. Extraction site reconstruction for alveolar ridge preservation. Part 1: rationale and materials selection. *J Oral Implantol* 2001;27:187-93.

7. Froum S, Cho SC, Rosenberg E, Rohrer M, Tarnow D. Histological comparison of healing extraction sockets implanted with bioactive glass or demineralized freeze-dried bone allograft: a pilot study. *J Periodontol* 2002

;73:94-102.

8. Block MS. Treatment of the single tooth extraction site. *Oral Maxillofac Surg Clin North Am* 2004;16:41-63,

9. Reddi AH, Wientroub S, Muthukumaran N. Biologic principles of bone induction. *Orthop Clin North Am* 1987;18:207-12.

10. Schwartz Z, Somers A, Mellonig JT, Carnes DL Jr, Dean DD, Cochran DL, Boyan BD. Ability of commercial demineralized freeze-dried bone allograft to induce new bone formation. *J Periodontol* 1998;69:470-8.

11. Zhang M, Powers RM Jr, Wolfinbarger L Jr. A quantitative assessment of osteoinductivity of human demineralized bone matrix. *J Periodontol* 1997;68:1076-84.

12. Becker W, Urist MR, Tucker LM, Becker BE, Ochsenbein C. Human demineralized freeze-dried bone: inadequate induced bone formation in athymic mice. A preliminary report. *J Periodontol* 1995;66:822-8.

13. Buser D, Hoffmann B, Bernard JP, Lussi A, Mettler D, Schenk RK. Evaluation of filling materials in membrane--protected bone defects. A comparative histomorphometric study in the mandible of miniature pigs. *Clin Oral Implants Res* 1998;9:137-50.

14. Hämmerle CH, Chiantella GC, Karring T, Lang NP. The effect of a deproteinized bovine bone mineral on bone regeneration around titanium dental implants. *Clin Oral Implants Res* 1998;9:151-62.

15. Artzi Z, Nemcovsky CE. The application of deproteinized bovine bone mineral for ridge preservation prior to implantation. Clinical and histological observations in a case report. *J Periodontol* 1998;69:1062-7.

16. Artzi Z, Tal H, Dayan D. Porous bovine bone mineral in healing of human extraction sockets. Part 1: histomorphometric evaluations at 9 months. *J Periodontol* 2000;71:1015-23.

17. Artzi Z, Tal H, Dayan D. Porous bovine bone mineral in healing of human extraction sockets: 2. Histochemical observations at 9 months. *J Periodontol* 2001;72:152-9.

18. Sogal A, Tofe AJ. Risk assessment of bovine spongiform encephalopathy transmission through bone graft material derived from bovine bone used for dental applications. *J Periodontol* 1999;70:1053-63.

19. La Gatta A, De Rosa A, Laurienzo P, Malinconico M, De Rosa M, Schiraldi C. A novel injectable poly(epsilon-caprolactone)/calcium sulfate system for bone regeneration: synthesis and characterization. *Macromol Biosci* 2005;5(11):1108-17.

20. Piattelli A, Scarano A, Mangano C. Clinical and histologic aspects of biphasic calcium phosphate ceramic (BCP) used in connection with implant placement. *Biomaterials* 1996;17:1767-70.

21. Cordaro L, Bosshardt DD, Palattella P, Rao W, Serino G, Chiapasco M. Maxillary sinus grafting with Bio-Oss or Straumann Bone Ceramic:

histomorphometric results from a randomized controlled multicenter clinical trial. *Clin Oral Implants Res* 2008;19:796-803.

22. Botticelli D, Berglundh T, Lindhe J. Hard-tissue alterations following immediate implant placement in extraction sites. *J Clin Periodontol* 2004;31:820 - 828.

23. Araújo MG, Sukekava F, Wennstrom JL, Lindhe J. Ridge alterations following implant placement in fresh extraction sockets: an experimental study in the dog. *J Clin Periodontol* 2005;32:645 - 652.

24. Araújo M, Linder E, Wennstrom J, Lindhe J. The influence of Bio-Oss Collagen on healing of an extraction socket: an experimental study in the dog. *Int J Periodontics Restorative Dent* 2008;28:123 - 135.

25. De Coster P, Browaeys H, De Bruyn H. Healing of extraction sockets filled with BoneCeramic(R) prior to implant placement: preliminary histological findings. *Clin Oral Implants Res* 2011;13:34-45.

26. Froum SJ, Wallace SS, Cho SC, Elian N, Tarnow DP. Histomorphometric comparison of a biphasic bone ceramic to anorganic bovine bone for sinus augmentation: 6- to 8-month postsurgical assessment of vital bone formation. A pilot study. *Int J Periodontics Restorative Dent* 2008;28:273-81.

26. Carmagnola D, Adriaens P, Berglundh T. Healing of human extraction sockets filled with Bio-Oss. *Clin Oral Implants Res* 2003;14:137-43.

27. Elian N, Cho SC, Froum S, Smith RB, Tarnow DP. A simplified socket classification and repair technique. *Pract Proced Aesthet Dent* 2007;19:99-104.