



저작자표시-비영리-변경금지 2.0 대한민국

이용자는 아래의 조건을 따르는 경우에 한하여 자유롭게

- 이 저작물을 복제, 배포, 전송, 전시, 공연 및 방송할 수 있습니다.

다음과 같은 조건을 따라야 합니다:



저작자표시. 귀하는 원저작자를 표시하여야 합니다.



비영리. 귀하는 이 저작물을 영리 목적으로 이용할 수 없습니다.



변경금지. 귀하는 이 저작물을 개작, 변형 또는 가공할 수 없습니다.

- 귀하는, 이 저작물의 재이용이나 배포의 경우, 이 저작물에 적용된 이용허락조건을 명확하게 나타내어야 합니다.
- 저작권자로부터 별도의 허가를 받으면 이러한 조건들은 적용되지 않습니다.

저작권법에 따른 이용자의 권리는 위의 내용에 의하여 영향을 받지 않습니다.

이것은 [이용허락규약\(Legal Code\)](#)을 이해하기 쉽게 요약한 것입니다.

[Disclaimer](#)

2015년 8월

석사학위논문

2015년 8월
석사학위 논문

골 시멘트 보강술 및 경피적 단
분절 고정술이 쿨멜씨 병에 대한
효과적인 치료법이 될 수 있는
가?

골 시멘트 보강술 및 경피적 단분절 고정술이 쿨멜씨 병에 대한 효과적인 치료법이 될 수 있는가?

조선대학교 대학원

의학과

왕의석

왕의석

골 시멘트 보강술 및 경피적 단분절 고정술이 쿨멜씨 병에 대한 효과적인 치료법이 될 수 있는가?

Bone cement-augmented percutaneous short segment fixation : An effective treatment for Kummell's disease?

2015년 8월 25일

조 선 대 학 교 대 학 원

의 학 과

왕 의 석

골 시멘트 보강술 및 경피적 단분절 정술이 콧물씨 병에 대한 효과적인 요법이 될 수 있는가?

지도교수 김 석 원

이 논문을 의학 석사학위신청 논문으로 제출함

2015년 4월

조 선 대 학 교 대 학 원

의 학 과

왕 의 석

왕의석의 석사학위논문을 인준함

위원장 조선대학교 교 수 이 승 명 (인)

위 원 조선대학교 교 수 김 석 원 (인)

위 원 조선대학교 교 수 주 창 일 (인)

2015년 5월

조 선 대 학 교 대 학 원

목 차

ABSTRACT	3
I. 서론	5
II. 대상 및 방법	5
III. 결과	7
IV. 고찰	8
V. 결론	10
참고문헌	11

표 목 차

Table 1	13
Fig.1	13
Fig.2	14
Fig.3	14
Fig.4	15
Fig.5	15
Fig.6	16

ABSTRACT

Bone cement-augmented percutaneous short segment fixation : An effective treatment for Kummell' s disease?

Wang Ui suk

Advisor : Prof. Kim seok won, Ph.D.

Department of Medicine

Graduate School of Chosun University

Objective:

The aim of this prospective study was to evaluate the efficacy of bone cement-augmented percutaneous short segment fixation for treating Kummell' s disease accompanied by severe osteoporosis.

Methods:

From 2009 to 2013, ten patients with single-level Kummell' s disease accompanied by severe osteoporosis were enrolled in this study. After postural reduction for 1-2 days, bone cement-augmented percutaneous short segment fixation was performed at one level above, one level below, and at the collapsed vertebra. Clinical results, radiological parameters, and related complications were assessed preoperatively and at 1 month and 12 months after surgery.

Results:

Prior to surgery, the mean pain score on the visual analogue scale was 8.5.

One month after the procedure, this score improved to 2.2, and the improvement was maintained at 12 months after surgery. The mean preoperative vertebral height loss was 48.2%, and the surgical procedure reduced this loss to 22.5%. In spite of some recurrent height loss, significant improvement was achieved at 12 months after surgery compared to preoperative values. The kyphotic angle improved significantly from $22.4 \pm 4.9^\circ$ before the procedure to $10.1 \pm 3.8^\circ$ after surgery. The improved angle was maintained at 12 months after surgery despite a slight correction loss. No patient sustained adjacent fractures after bone cement-augmented percutaneous short segment fixation during the follow-up period. Asymptomatic cement leakage into the paravertebral area was observed in one patient, but no major complications were seen.

Conclusion:

Bone cement-augmented percutaneous short segment fixation can be an effective and safe procedure for Kummell' s disease.

Key Words : Osteonecrosis · Screw · Cement.

INTRODUCTION

Delayed post-traumatic vertebral collapse, characterized by painful kyphosis that develops several weeks or months following an injury after a symptom-free period, was first described by the German surgeon Hermann Kummell⁸⁾. Multiple synonymous terms have been used to describe Kummell's disease, including delayed post-traumatic vertebral collapse, non-union of a compression fracture, vertebral osteonecrosis, and intravertebral pseudarthrosis^{7,12)}.

For Kummell's disease with persistent pain and without neurological symptoms, percutaneous vertebroplasty (VP) or balloon kyphoplasty (KP) has been known to achieve good results^{5,10)}. However, more recent studies hypothesize that the rate of osteolysis among patients with Kummell's disease is greater than the rate of bone callus formation. As a result, following VP or KP, accelerated osteolysis may occur and displace the bone cement, and bone cement augmentation procedures such as VP and KP alone for Kummell's disease, even without neurologic deficits, often result in bone cement displacement^{9,14,15)}. Nowadays some good clinical outcomes are reported with bone cement augmented short segment fixation with thoracolumbar burst fractures regardless of osteoporosis⁶⁾.

As far as the authors' knowledge, however, there is no report for Kummell's disease prospectively investigating the clinical outcome of bone cement augmented percutaneous short segment fixation.

The purpose of this study was to evaluate whether bone cement-augmented percutaneous screw fixation could be a standard treatment option for Kummell's disease without neurologic deficits.

MATERIAL AND METHODS

From 2009 to 2013, ten patients (2 males and 8 females) with Kummell's disease accompanied by severe osteoporosis were enrolled in this study. The inclusion criteria were 1) intact neurological status despite single-level Kummell's disease, 2) age 65 years and over, 3) severely osteoporotic spine (mean T-score on bone mineral densitometry < -3.0 , and 4) newly diagnosed osteoporosis. Kummell's disease was diagnosed according to intravertebral cleft (IVC) signs on simple lateral radiographs and computed tomography (CT) or evidence of osteonecrosis with a fluid sign on magnetic resonance imaging (MRI) (Fig. 1). Patients with conditions requiring anterior decompression to ameliorate neurologic deficits, multiple compression fractures, or a history of previous vertebroplasty or spinal surgery were excluded.

Surgical procedure

After sufficient explanation of procedure-related complications, postural reduction to achieve hyperextension was conducted for 1–2 days, using a soft roll under the collapsed vertebra with the patient in the supine position. Bone cement-augmented percutaneous screw fixation confined to one level above, one level below, and at the collapsed vertebra itself was performed. Bone cement augmentation was achieved using polymethylmethacrylate (PMMA), which was injected under C-arm guidance through a vertebroplasty needle. Approximately 2.5 cc of PMMA was injected through the vertebroplasty needle, a total of 5 cc per vertebra.

Vertebral height loss was measured at the site of anterior collapse on lateral radiograph or sagittal CT scan. The vertebral heights were reported as fractions of anterior height between fractured vertebra and normal height of adjacent one level below the fractured vertebra. Kyphotic angle (Cobb's angle) was measured by drawing a straight line from the superior endplate of one level above the fractured body and a straight line from the inferior endplate of one level below the fractured body on a true lateral radiograph.

Imaging and clinical findings, including the involved level, vertebral height loss, evidence of local kyphosis, clinical outcomes, and complications were analyzed.

Statistical analysis

Statistical analysis was performed using SAS 6.12 (SAS Institute, Inc., Cary, NC, USA). Mean value (MV) and standard deviation (SD) were calculated for all measurements. Comparisons between different time points were made using the Wilcoxon signed-rank test. P values < 0.05 were considered statistically significant.

RESULTS

All fractures occurred at the thoracolumbar junction. Anatomic distribution of the collapsed vertebrae was as follows: T11 (n = 1), T12 (n = 3), L1 (n = 5), and L2 (n = 1). Mean age of the patients was 75.4 years (range, 64–85 years). As mentioned above, all patients had severely osteoporotic spines, with a mean T-score of -4.06 (Table 1). Mean operation time was 52 minutes and no patient needed a drainage catheter or blood transfusion. All patients were able to ambulate at 24 hours after surgery wearing a thoracolumbosacral orthosis (TLSO).

Restoration of vertebral height

Preoperatively, mean vertebral body height loss was 48.2%. Simple lateral radiographs taken 1 month after the surgical procedure showed that mean vertebral height loss was 22.5%. Despite significant improvement compared to the preoperative value, mean vertebral height loss was 28.5% at 12 months after surgery (P = 0.020). During the follow-up period, vertebral

height loss increased by 6.0 (Fig. 2).

Overall reduction of kyphotic deformity

The kyphotic angle improved significantly from $22.4 \pm 4.9^\circ$ before surgery to $10.1 \pm 3.8^\circ$ at 1 month after surgery. The improved alignment, as observed on a true lateral X-ray, was maintained at 12 months after surgery in spite of some correction loss (Fig. 3).

Clinical outcomes

At 12 months after surgery, all patients achieved a good or excellent outcome according to modified MacNab's criteria. Prior to surgery, the mean pain score (visual analogue scale) was 8.5. This score decreased to 2.2 at 1 month after surgery and it was maintained at 12 months after the procedure (Fig. 4).

Asymptomatic cement leakage into the paravertebral area through venous channel was observed in one patient (Fig. 5). However, no major complications such as spinal cord compression, pulmonary embolism, or serious infection were observed in any patient (Fig. 6).

DISCUSSION

Osteoporotic compression fractures are the most common spinal disorder in elderly patients. Most compression fractures heal within a few weeks or months, and it is believed that in most cases, they do not result in severe clinical problems¹⁰⁾.

Kummell's disease, by definition, is a spinal disorder characterized by vertebral body avascular necrosis occurring in a delayed fashion after minor trauma. It evolves according to the following 3 phases: (1) back pain

consequent to minor trauma, which progressively subsides, leading to an asymptomatic period; (2) recurrence of pain weeks to months after the initial insult; and (3) appearance of kyphotic spine deformities without any further trauma. All 3 phases must present progressively to lead to the diagnosis of Kummell's disease. A classic finding is the presence of an intravertebral vacuum cleft on plain radiograph, better appreciated on anteroposterior view, on CT or MRI¹¹⁾.

Cases of Kummell's disease with prolonged severe back pain refractory to conservative treatment, with or without neurologic deficits, require surgical treatment. Surgical approaches for Kummell's disease differ between patients with neurological symptoms and those without neurological symptoms. For neurologically impaired patients, the aim of surgery is to decompress the spinal cord, restore the spinal physiological curvature, and maintain spinal stability. The surgical modes include anterior, posterior, or combined anterior and posterior approaches¹³⁾.

For patients without neurological symptoms, the objective is to eliminate motion at the fracture site and restore the spinal curvature. Certain authors have reported that for Kummell's disease without neurological symptoms, VP or KP achieves good clinical results^{1,2)}. This assumes that pain relief can be expected if the IVC is filled with bone cement and stabilized because unstable fractures and motion within the IVC produce severe and persistent pain.

However, Heo et al.³⁾ assert that bone cement augmentation procedure alone for treating Kummell's disease is associated with recurrent collapse as well as dislodged or fragmented bone cement. They reported that the incidence of re-collapse after VP was significantly higher in patients with IVC(28.6%) than in those without IVC(1.2%). Furthermore, Kummell's disease may present with cortical breakage or cord compression, both of which are contraindications for cement augmentation⁴⁾. Lee et al.¹⁰⁾ reported in their clinical study that restored vertebral heights and corrected kyphotic angles were reaggravated, suggesting that vertebral osteonecrosis progresses after a

bone cement augmentation procedure alone. They concluded that stabilization by open surgery should be considered as another option for Kummell's disease without neurologic deficits. Patients with Kummell's disease are usually elderly and have severe osteoporotic spines ; thus, multisegment fixation with bone fusion by a posterior approach should generally be considered performed. However, this requires extensive dissection of paraspinal muscles of the back and resection of posterior elements of the spine, making it difficult to preserve motion segments. Moreover, elderly patients do not easily tolerate a long level fusion. Therefore, the development of a minimally invasive and effective treatment is required. For Kummell's disease without neurologic deficits, we performed bone cement-augmented percutaneous short segment fixation. This surgical method provides several advantages over long level fixation. The main advantage is that it more effectively preserves motion segments. Second, it minimizes posterior pedicle screw stress through anterior support provided by the vertebral bone cement. Third, it results in immediate pain relief due to stabilization with elimination of donor site pain, reduction in blood loss, and decrease in operation time.

In the current study, we used PMMA for bone cement augmentation, which achieved effective pain relief and good postoperative kyphosis correction. At 12 months after surgery, slight loss of kyphosis corrections were observed compared with measurements at 1 month after the surgery, but the differences were not statistically significant. However, comparative trials in a larger population with longer follow-up times are required to verify our results.

CONCLUSION

Bone cement-augmented percutaneous short segment fixation can be useful for the treatment of Kummell's disease without neurologic deficits in elderly. This technique was found to produce excellent pain relief and correction of kyphotic deformities.

참고 문헌

1. Do HM, Jensen ME, Marx WF, Kallmes DF : Percutaneous vertebroplasty in vertebral osteonecrosis (Kummell's spondylitis). *Neurosurgery Focus* 7(1) : e2, 1999
2. [Feng SW](#), [Chang MC](#), [Wu HT](#), [Yu JK](#), [Wang ST](#), [Liu CL](#) : Are intravertebral vacuum phenomena benign lesions? *Eur Spine J* 20(8) : 1341-1348, 2011
3. Heo DH, Chin DK, Yoon YS, Kuh SU : Recollapse of previous vertebral compression fracture after percutaneous vertebroplasty. *Osteoporosis Int* 20 : 473-480, 2009
4. [HS Wang](#), [HS Kim](#), [CI Ju](#), [SW Kim](#) : Delayed bone cement displacement following balloon kyphoplasty. *J Korean Neurosurg Soc* 43(4) : 212-214, 2008
5. Jang JS, Kim DY, Lee SH : Efficacy of percutaneous vertebroplasty in the treatment of intravertebral pseudarthrosis associated with noninfected avascular necrosis of the vertebral body. *Spine* 28(14) : 1588-1592, 2003
6. [Kim HS](#), [Kim SW](#), [Ju CI](#), [Lee SM](#), [Shin H](#) : Short segment fixation for thoracolumbar burst fracture accompanying osteopenia : a comparative study. *J Korean Neurosurg Soc* 53(1) : 26-30, 2013
7. [Kim KT](#), [Suk KS](#), [Kim JM](#), [Lee SH](#) : Delayed vertebral collapse with neurological deficits secondary to osteoporosis. *International Orthopaedics* 27(2) : 65-69, 2003
8. Kummell H : Die rarefizierende ostitis der wirbelkrper. *Deutsche Med* 21 : 180-181, 1982
9. [Laredo JD](#) : Expert's comment concerning Grand Rounds case entitled "Kummell's disease: delayed post-traumatic osteonecrosis of the vertebral

body" (by R. Ma, R. Chow, F. H. Shen). [Eur Spine J](#) 19(7) : 1071-1072, 2010

10. Lee K, Lee SG, Kim WK, Yoo CJ, Park CW : Comparison vertebroplasty with kyphoplasty in delayed post-traumatic osteonecrosis of a vertebral body (Kummell's disease). [Korean J Spine](#) 5 : 70-76,2008

11. [Malghem J](#), [Maldague B](#), [Labaisse MA](#), [Dooms G](#), [Duprez T](#), [Devogelaer JP](#), et al.

: Intravertebral vacuum cleft: changes in content after supine positioning. [Radiology](#)187(2):483-487,1993

12. [Saita K](#), [Hoshino Y](#), [Kikkawa I](#), [Nakamura H](#) : Posterior spinal shortening for paraplegia after vertebral collapse caused by osteoporosis. [Spine \(Phila Pa 1976\)](#) 25(21) : 2832-2835, 2000

13. [Suk SI](#), [Kim JH](#), [Lee SM](#), [Chung ER](#), [Lee JH](#) : Anterior-posterior surgery versus posterior closing wedge osteotomy in posttraumatic kyphosis with neurologic compromised osteoporotic fracture. [Spine \(Phila Pa 1976\)](#) 15;28 (18) : 2170-2175, 2003

14. [Wagner AL](#), [Baskurt E](#) : Refracture with cement extrusion following percutaneous vertebroplasty of a large interbody cleft. [AJNR Am J Neuroradiol](#) 27(1) : 230-231, 2006

15. [Wang HS](#), [Kim HS](#), [Ju CI](#), [Kim SW](#) : Delayed bone cement displacement following balloon kyphoplasty. [J Korean Neurosurg Soc](#) 43(4) : 212-214, 2008

Table 1. Clinical and radiological data for the patients

Case	Age/gender	Level	BMD	Cleft component	Complication	Result
1	T12	65/F	-4.1	Fluid	-	Excellent
2	T12	85/F	-4.2	Fluid	Cement leakage	Excellent
3	L1	83/M	-3.4	Gas	-	Good
4	T12	68/F	-4.7	Gas	-	Excellent
5	L2	74/F	-3.6	Fluid	-	Good
6	L1	78/M	-3.9	Fluid	-	Good
7	L1	77/F	-4.5	Gas	-	Excellent
8	T11	67/F	-4.2	Fluid	-	Good
9	L1	80/F	-3.9	Fluid	-	Excellent
10	L1	78/F	-4.1	Gas	-	Excellent

BMD = Bone mineral densitometry

Fig. 1. The component of intravertebral cleft is divided into gas and fluid.

A : Intravertebral gas at L1 level is a computed tomographic finding indicative of Kummell's disease.

B : Intravertebral fluid filled cleft at L1 level on magnetic resonance imaging is also characteristic of Kummell's disease.

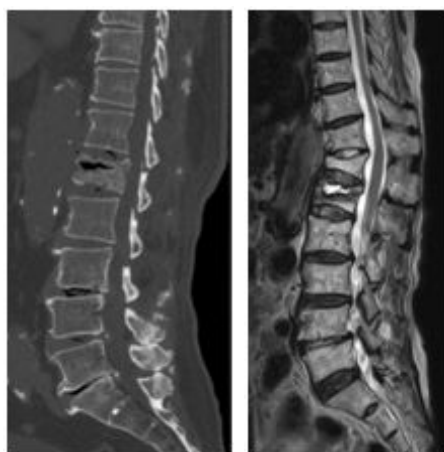
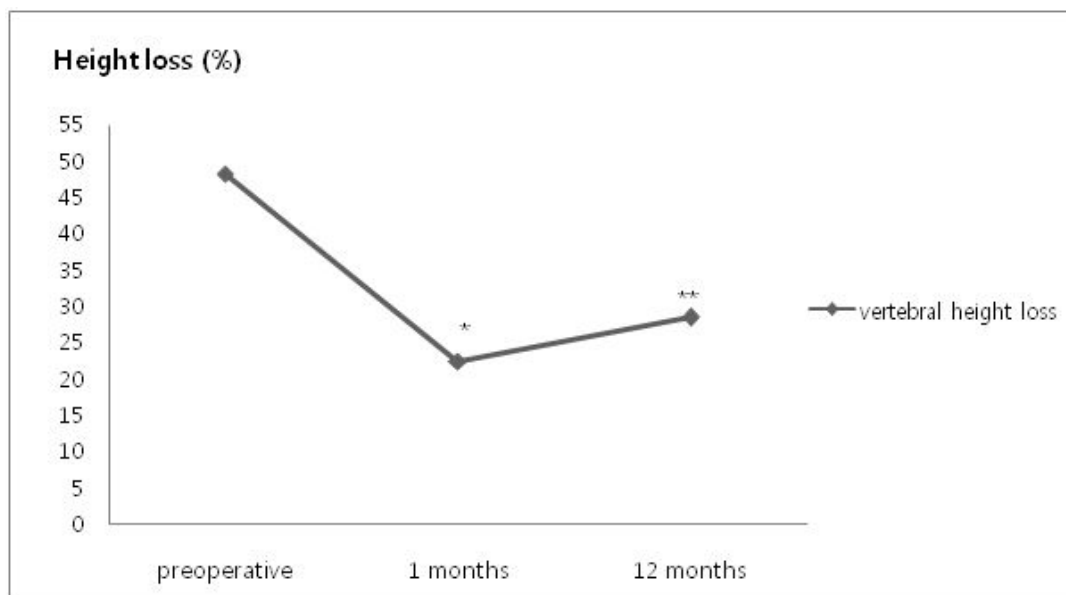


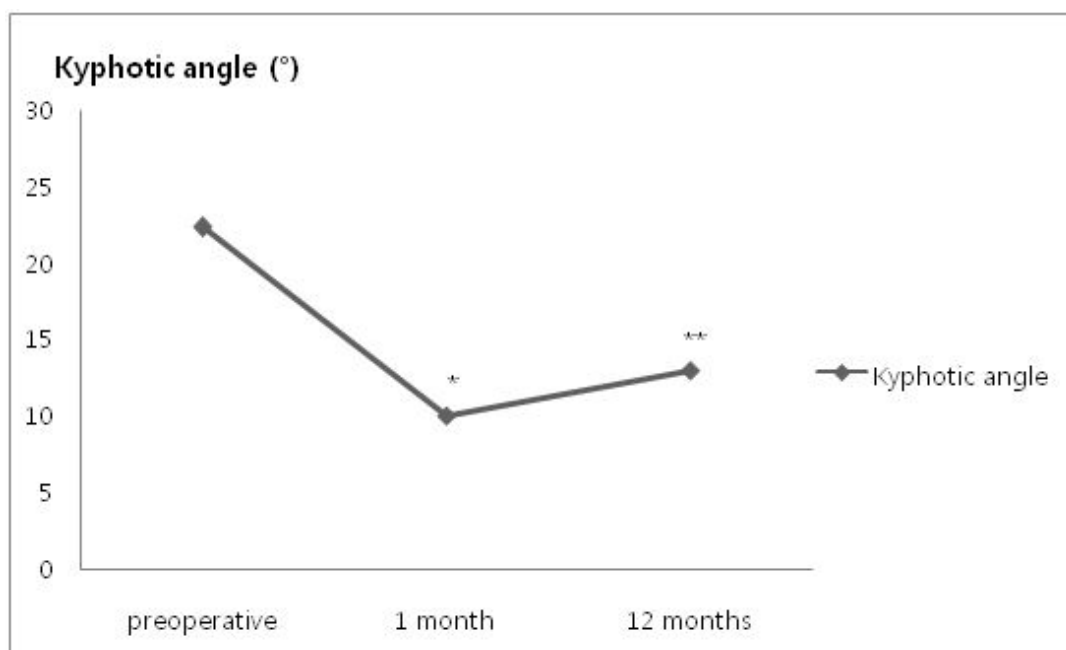
Fig. 2. Restoration of vertebral height.



*preoperative versus 1 month, $P = 0.002$

**preoperative versus 12 months, $P = 0.01$

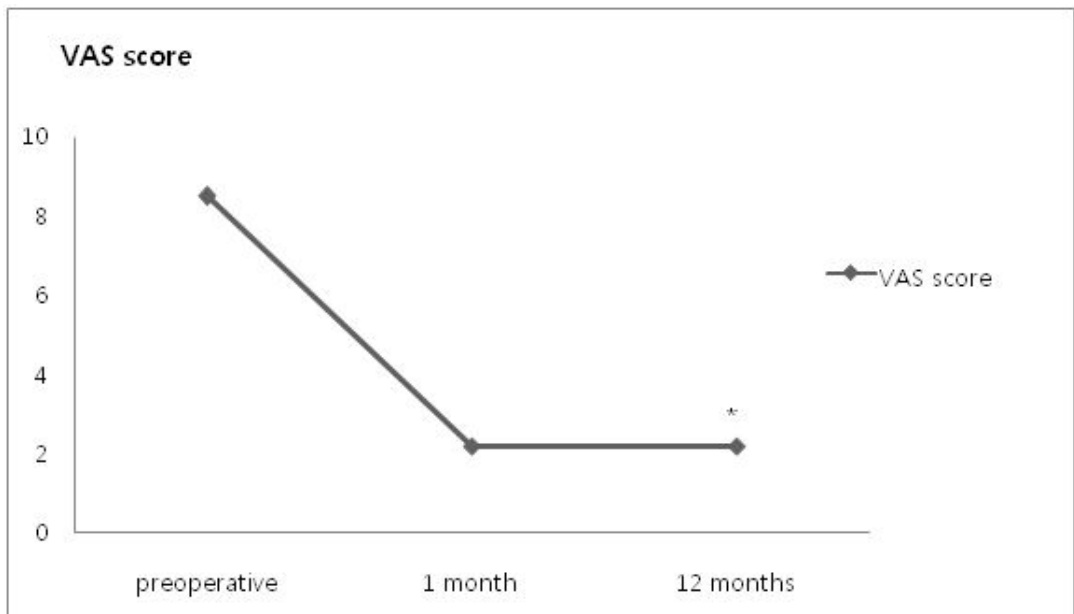
Fig. 3. Changes in kyphotic angle.



*preoperative versus 1 month, $P = 0.005$

**preoperative versus 12 months, $P = 0.018$

Fig. 4. Improvement in pain score.



* $P < 0.001$, preoperative versus final follow-up

VAS = visual analogue scale

Fig. 5. Osteoporotic compression fracture with an intravertebral cleft at the T12 level in a 85-year-old female.

A : T2-weighted magnetic resonance image reveals a fluid filled IVC, indicative of Kummell's disease.

B&C : Simple radiographs after bone cement-augmented percutaneous short segment screw fixation show restored vertebral height and improved kyphotic deformity in spite of cement leakage through venous channel (arrows).

D&E : Simple radiographs taken at 12 months after surgery show some aggravation of kyphosis.

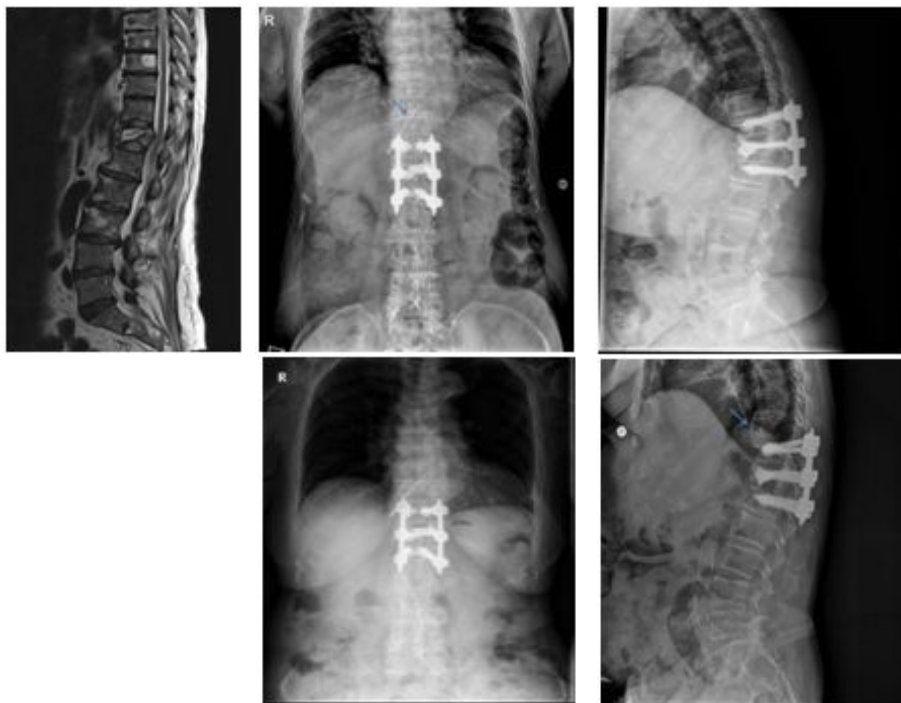
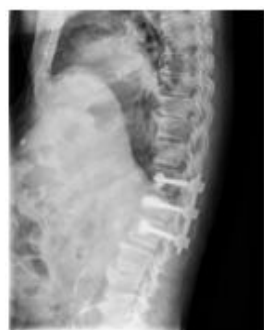
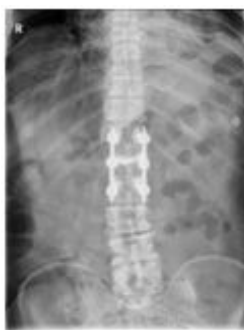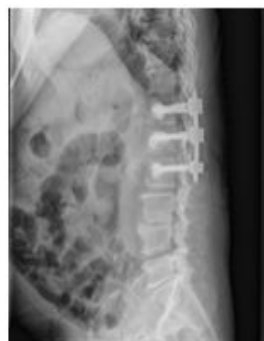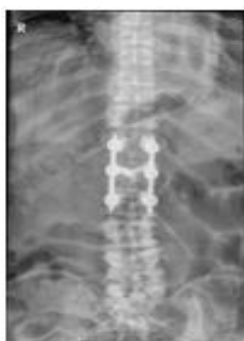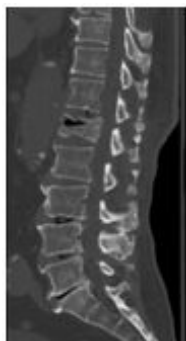Fig. 6. Osteoporotic compression fracture with an intravertebral cleft (IVC) at the L1 level in a 83-year-old male.

A: Computed tomography scan shows a gas filled IVC, indicative of Kummell's disease.

B & C :Simple radiographs after bone cement-augmented percutaneous short segment screw fixation show restored vertebral height and improved kyphotic deformity.

D & E :Simple radiographs taken at 12 months after surgery reveal a well-maintained kyphotic angle.



저작물 이용 허락서

학 과	의학과	학 번	20137390	과 정	석사
성 명	한글: 왕의석 한문: 王宜錫 영문: Wang Ui suk				
주 소	광주광역시 북구 용봉동 금호아파트 101동 1802호				
연락처	E-MAIL : prius777@naver.com				
논문제목	<p>한글 : 골 시멘트 보강술 및 경피적 단분절 고정술이 쿨멜씨 병에 대한 효과적인 치료법이 될 수 있는가?</p> <p>영어 : Bone cement-augmented percutaneous short segment fixation : An effective treatment for Kummell's disease?</p>				

본인이 저작한 위의 저작물에 대하여 다음과 같은 조건아래 조선대학교가 저작물을 이용할 수 있도록 허락하고 동의합니다.

- 다 음 -

1. 저작물의 DB구축 및 인터넷을 포함한 정보통신망에의 공개를 위한 저작물의 복제,
기억장치에의 저장, 전송 등을 허락함
2. 위의 목적을 위하여 필요한 범위 내에서의 편집·형식상의 변경을 허락함. 다만,
저작물의 내용변경은 금지함.
3. 배포·전송된 저작물의 영리적 목적을 위한 복제, 저장, 전송 등은 금지함.
4. 저작물에 대한 이용기간은 5년으로 하고, 기간종료 3개월 이내에 별도의 의사
표시가 없을 경우에는 저작물의 이용기간을 계속 연장함.
5. 해당 저작물의 저작권을 타인에게 양도하거나 또는 출판을 허락을 하였을
경우에는 1개월 이내에 대학에 이를 통보함.
6. 조선대학교는 저작물의 이용허락 이후 해당 저작물로 인하여 발생하는 타인에
의한
권리 침해에 대하여 일체의 법적 책임을 지지 않음
7. 소속대학의 협정기관에 저작물의 제공 및 인터넷 등 정보통신망을 이용한
저작물의
전송·출력을 허락함.

동의여부 : 동의(O) 반대()

2015 년 4 월 15일

저작자: 왕의석 (서명 또는 인)

조선대학교 총장 귀하